

Annotating Retina Fundus Images for Teaching and Learning Diabetic Retinopathy Software

Rakibul Alam¹, Bruce Poon^{1,2}, Mahmood Kazi Mohammed^{1,3}, M. Ashraful Amin¹, Hong Yan^{2,4}

¹Computer Vision and Cybernetics Group, Department of Computer Science & Engineering, Independent University, Bangladesh

²School of Electrical & Information Engineering, University of Sydney, NSW 2006, Australia

³Sir Salimullah Medical College, 40/1, Tipu Sultan Rd, Dhaka, Bangladesh

⁴Department of Electronic Engineering, City University of Hong Kong, Hong Kong, China

E-MAIL: rakeeb@live.com, bruce.poon@ieee.org, mkmohammed86@gmail.com, aminmdashraful@gmail.com, h.yan@cityu.edu.hk

Abstract— With the improvement in IT industry, more and more application of computer software is introduced in teaching and learning. In this paper, we discuss the development process of such software. Diabetic Retinopathy is a common complication for diabetic patients. It may cause sight loss if not treated early. There are several stages of this disease. Fundus imagery is required to identify the stage and severity of the disease. Due to the lack of proper dataset of the fundus images and proper annotation, it is very difficult to perform research on this topic. Moreover, medical students are often facing difficulty with identifying the diseases in later stage of their practice as they may not have seen a sample of all of the stages of Diabetic Retinopathy problems. To mitigate the problem, we have collected fundus images from different geographic area of Bangladesh and designed an annotation software to store information about the patient, the infection level and their locations in the images. Sometimes, it is difficult to select all appropriate pixels of the infected region. To resolve the issue, we have introduced a K nearest neighbor (KNN) based technique to accurately select the region of interest (ROI). Once an expert (ophthalmologist) has annotated the images, the software can be used by the students for learning.

Keywords—teaching and learning Software; diabetic retinopathy; medical image annotation; expert medical system; K-nearest neighbor.

I. INTRODUCTION

Among many complications due to diabetics, diabetic retinopathy [1] is the most common and can lead to severe eye damages if not treated early. Sometimes, it starts with no early warning. If untreated, it can cause severe proliferation. At the early stage, namely nonproliferative stage, only micro-aneurysms occur. Micro-aneurysms are round shaped swelling in the retinal blood vessel. In the next phase, blood vessels that is responsible to supply nourishment to retina starts to block. This phase is moderate nonproliferative stage. If not treated, more blood vessels are blocked and start depriving areas of retina from blood supply which leads to proliferative stage. A precise dataset is needed so that further study on those retinopathy stages can be done. However, due to the lack of such dataset, we have attempted to create one which contains fundus images from different geographic areas of Bangladesh.

We have collected 625 fundus images from the health care providers. Patients' anonymity is ensured by producing a unique image identification number for each patient. Besides, we have developed software that can aid an expert to annotate the infections and symptoms of different levels of retinopathy. It is highly challenging for a human expert to accurately select the region of infection in the image. Sometimes, an expert may miss some pixels or regions here and there in the infected region. To overcome the problem, we have designed a neighborhood information based pixel clustering technique to include or reject those which are not the part of infected regions. This dataset with annotation software can be used later in further investigations on the field of diabetic retinopathy. It is also be a great aid to the medical students who are trying to learn about the retinopathy levels. Machine learning based models to correctly classify those levels are also possible using such datasets. Previously, we have worked on automated identification of retinal blood vessels [2] and optical disk [3] that are applicable to retina based biometric applications [4]. However, for diabetic retinopathy teaching and learning facility development, accuracy on annotation is on top priority while faster annotation is on low priority.

Figure 1 shows the anatomy of a human eye where we can see the location of Retina. Figure 2 shows retinal fundus image.

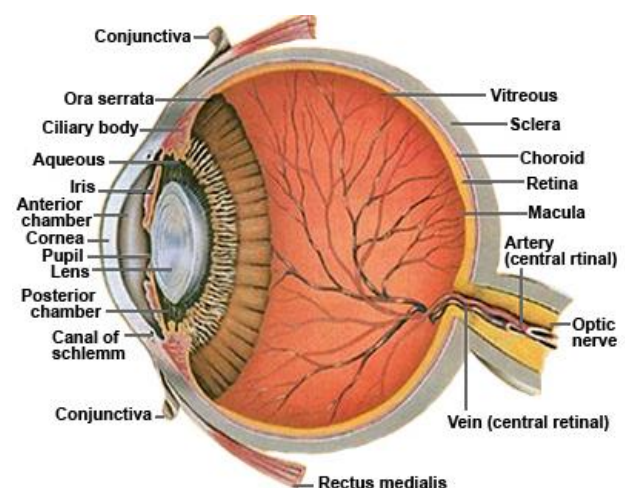


Fig. 1. Anatomy of a Human Eye

*This work is jointly supported by Independent University, Bangladesh and University Grants Commission of Bangladesh under HEQEP Number: CP-3359.

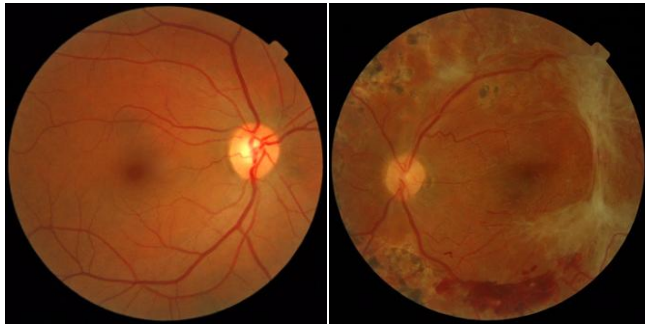


Fig. 2. Healthy retinal fundus image (left) and a retinal fundus image with pathology (right)

II. DIABETIC RETINOPATHY

Diabetic Retinopathy is the most common diabetic eye disease all over the world. The primary cause of the disease is uncontrolled proliferation of retinal vessels. For some people with diabetic retinopathy, blood vessels may swell and leak fluid. For others, abnormal new blood vessels grow on the surface of the retina. Retina is the light-sensitive tissue located at the back of the eye. A healthy retina is necessary for good vision. Different diabetic retinopathy levels are explained below.

A. Nonproliferative Retinopathy

At this earliest stage, there is no symptom to any infections. Nothing is visible to naked eye and patient also retains 20/20 vision. However, the tiny micro-aneurysms can be visible to fundus imageries. The density of those micro-aneurysms defines the level of non-proliferative retinopathy. Non proliferative retinopathy can be subdivided into four categories such as – *very mild, mild, moderate and severe* [1].

1) Very mild Nonproliferative Retinopathy.

In this stage only micro-aneurysms exists. Patient's vision is perfect. No other complication is visible.

2) Mild Nonproliferative Retinopathy.

Complication starts to grow in this stage. Micro-aneurysms, retinal hemorrhage, cotton wool spots can be visible. No Intra-retinal Micro-vascular Abnormality (IRMA) is visible.

3) Moderate Nonproliferative Retinopathy

In this stage, severe retinal hemorrhage exist in 1- 3 quadrants of the retina. IRMA exists and cotton wool spots are commonly present in the retina.

4) Severe Nonproliferative Retinopathy

This is the most complicated nonproliferative stage. Severe hemorrhage starts to grow in all four quadrants of the retina. A significant amount of venous beading exists in 2 or more quadrants. Sometimes, IRMA exists in more than one quadrant.

B. Proliferative Retinopathy

As the disease progresses, some blood vessels that nourish the retina are blocked and stop supplying required nutrients to some parts of retina. Those zones with malnutrition then send

signals to grow more blood vessels so that nutrients supply can be possible.

More blood vessels are blocked, depriving several areas of the retina with their blood supply. These areas of the retina send signals to the body to grow new blood vessels for nourishment. At this advanced stage, the signals sent by the retina for nourishment trigger the growth of new blood vessels. This condition is called proliferative retinopathy. These new blood vessels are abnormal and fragile. They grow along the retina and along the surface of the clear, vitreous gel that fills the inside of the eye. By themselves, these blood vessels do not cause symptoms or vision loss. However, they have thin, fragile walls. If they leak blood, severe vision loss and even blindness can result. Proliferative retinopathy can also be categorized into two stages – mild moderate and high risk [1].

1) Mild Moderate Stage

New blood vessels on the disk start to appear. However, the proliferation is not that severe.

2) High Risk Stage

In this stage, vessel proliferation becomes more severe and it may blur the normal sight.

III. EXISTING DATASETS

We have collected almost all the publicly available retinal fundus image datasets (databases). The Digital Retina Image for Vessel Extraction (DRIVE) [5] database contains 40 color retinal images, where 33 are healthy and 7 are pathological. The VARPA Retina Images for Authentication (VARIA) [6] database contains 233 grayscale images but with higher degree of magnification. The numbers of healthy and pathological images are not stated. Although VARIA dataset contains multiple images of same individuals, the images are extremely prone to noises due to the magnification or some other unknown cause.

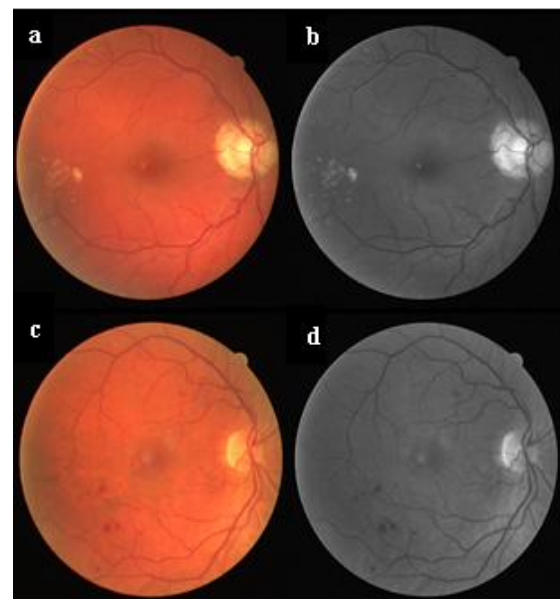


Fig. 3. Sample data from the DRIVE and MESSIDOR database

The VICAVER [7] dataset contains 58 color fundus images. Two databases that are solely established for detection of diabetic retinopathy are also used. They are standard diabetic retinopathy database, DIARETDB_01 [8] and digital retina images database, MESSIDOR [9]. DIARETDB_01 database contains 89 color fundus images and MESSIDOR contains 1200 color retinal fundus images with low to mild pathologies. Figure 3 shows sample images from DRIVE and MESSIDOR datasets.

IV. DATA COLLECTION

We have discussed various existing datasets and their characteristics in above section. However, due to the lack of proper Diabetic Retinopathy dataset, we have attempted to create a new dataset. Our main goal is to collect data from different geographic areas with all kinds of variations so that it reflects the whole picture of DR. To do so, we have contacted different health care providers from Bangladesh and asked them to provide the normal physiological information such as age, sex, blood pressure, level of diabetics, pulse-rate, etc. We have identified each patient with an image ID and made them anonymous in order to protect their health related privacy. Overall, we have collected 625 images from different geographic areas. Figure 4 shows the distribution of collected fundus imagery from patients with positive diabetic retinopathy.

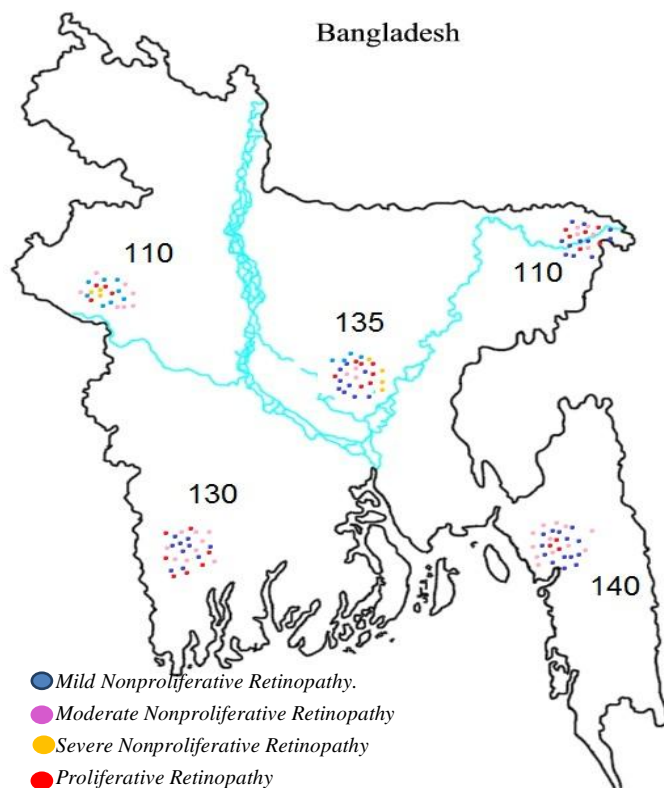


Fig. 4. Geographic distribution of collected fundus images

V. PROPOSED MODEL

The image annotation facility is crucial to create retinal dataset for diabetic retinopathy. An expert user can select the diabetic retinopathy level by examining the whole picture. There is a module where he can express his confidence level. We also feel the necessity of a description field where expert can express his remarks on the level of retinopathy. An array of general information related to patients, such as age, sex, blood pressure, level of diabetics, exposure to diabetics and pulse are added for future investigations.

In this image annotation software, we have added eleven different symptoms which are closely related to diabetic retinopathy. Those are Micro-aneurysms, Retinal Hemorrhages, Severe Retinal Hemorrhages, Exudates, Cotton wool spots, IRMA, Moderate IRMA, Micro-vascular Abnormalities, Venous Beading, New Vessels on Disk, and New Vessels on elsewhere. A description field is added to express the severity or mildness of the symptom.

The most crucial part of the software is the selection tools that can aid the expert to select the appropriate location where the symptom occurs. Our system provides four types of selection tools such as polygon selection, eclipse selection, point selection and free hand selection.

For data collection we have created an xml based archive system that accumulates data from the software front end. Because of the generic nature of xml tag based data archive, it can be accessible to any system that can parse xml tags. A fraction of a data archive file is shown Figure 5.

```
<root>
  <imageName>IM0001.jpg</imageName>
  <age>45</age>
  <sex>m</sex>
  <bloodPressure1>80</bloodPressure1>
  <bloodPressure2>120</bloodPressure2>
  <diabetics>7.0</diabetics>
  <yearsDiabetics>3</yearsDiabetics>
  <pulse>67</pulse>
  <retinopathyLevel>2</retinopathyLevel>
  <confidence>4</confidence>
  <imageDescription>mild</imageDescription>
  <objectCounter>2</objectCounter>
  <object>
    <objectName>Microaneurysms</objectName>
    <description>mild</description>
    <selectTool>eclipse</selectTool>
    <positions>1709 380 139 107</positions>
    <objectName>Cotton wool spots</objectName>
    <description>mild</description>
    <selectTool>polygon</selectTool>
    <positions>1434 1430 1430 1502 1580 1702
    </positions>
  </object>
</root>
```

Fig. 5. Data Structure of the xml data sheet

We have created an adaptive user interface as shown in Figure 6 that can aid to create datasets and help medical students to learn about retinal disorders.

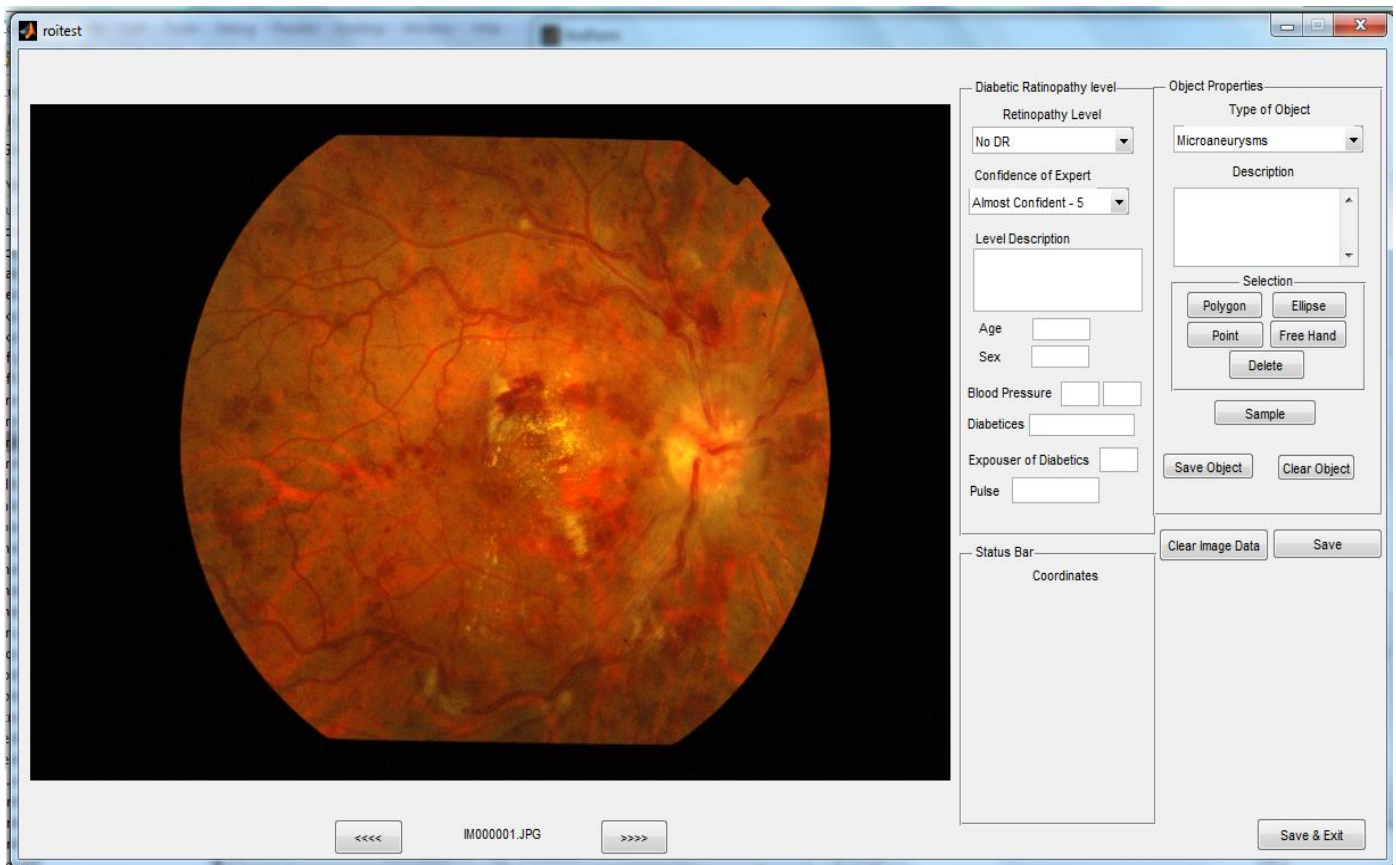


Fig. 6. User interface of the DR data annotation software.

It is clear from the Figure 5 that appropriate tags are used for the data annotation in xml data archive. Due to the xml based architecture, a hierarchical data structure is possible to develop. The hierarchy is explained in Figure 7.

The data annotation hierarchy starts with root. Root contains all the image information. Individual image contains information about the patients, diabetic retinopathy level and all the objects that are actually the symptoms of diabetic retinopathy.

In the third level of hierarchy, the object contains the object name (symptom name), description about the symptom, types of selection tool used by expert and the positions of the symptoms. Four selection tools that we have added in the data annotation software are shown in Figure 8. Since we know that it is difficult for human to exactly specify the Region of interest (ROI), it is sometimes convenient to expand or shrink the ROI based on the local neighborhood information. We have used the K nearest neighbor [10] classifier to identify whether a pixel is in the ROI or not.

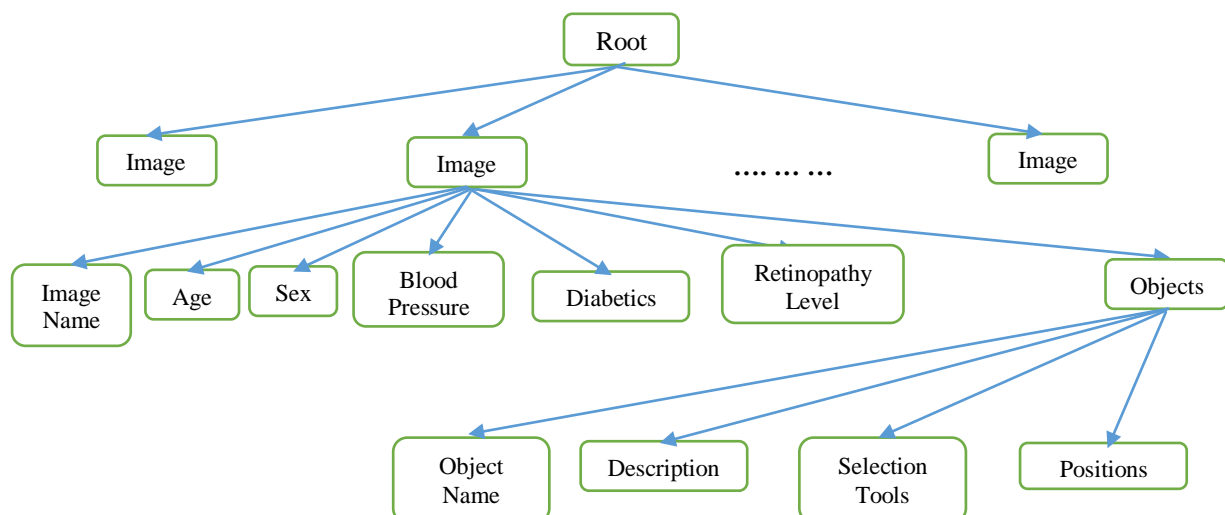


Fig. 7. Hierarchical Data.

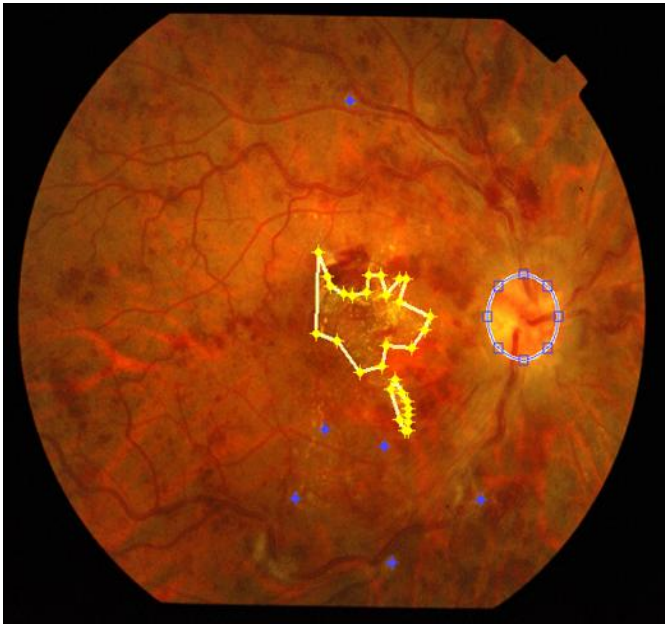


Fig. 8. Use of various Selection tools in our proposed model

Before the feature extraction, we have extracted the green channel of the image. Tiny micro-aneurysms and other symptoms are more visible in Green channel fundus image. Green channel of the sample image is shown in Figure 9.

On the neighborhood, we have used a window based classification. A predefined window is slide through the border region. Average intensity and standard deviation are taken as features to classify whether they are part of the original selection or not. Figure 10 shows the corrected form of selection after classifying the border regions with K-nearest neighbor classifier.

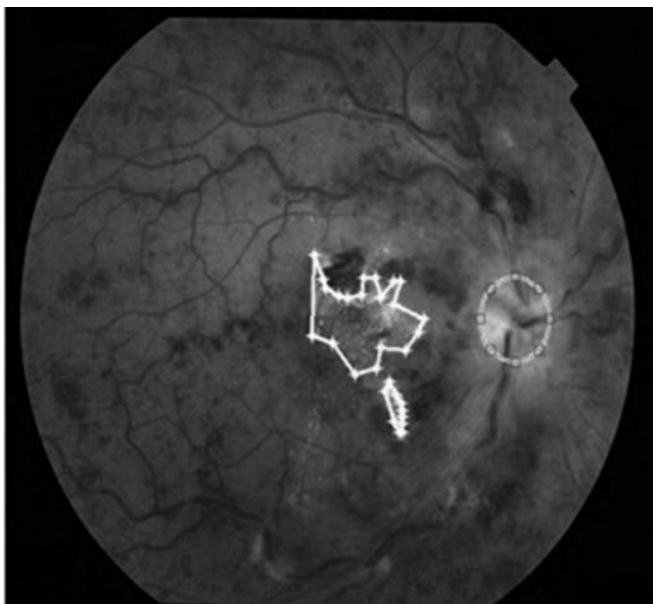

Fig. 9. Green Channel of the fundus image

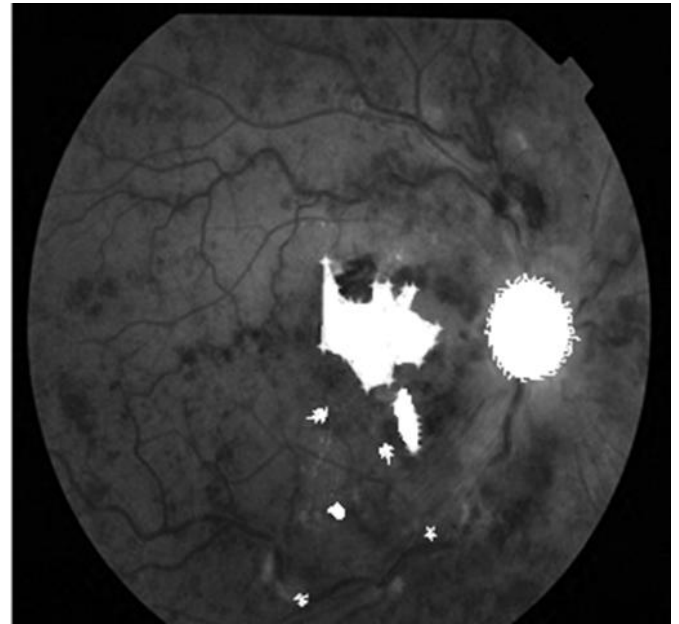


Fig. 10. ROI after KNN based border

VI. CONCLUSION AND FUTURE WORK

Diabetic retinopathy can lead to severe complications if it is not treated in early stage. Investigations in this area are difficult due to the lack of proper dataset. We have collected the fundus images from different geographic locations of Bangladesh. A software application with data achieve facility is introduced to properly annotate the medical data. This dataset will also help the medical students to learn the symptoms of the disease. To ease the data annotation, we introduce KNN based classifier that can select the region which add or shrink the region based on local neighborhood information.

Although instrument for automatic detection of Diabetic Retinopathy is available in the developed countries, they are expensive to acquire. Our software system can provide an economical alternative for the eye doctors and optometrists in the developing countries to easily analysis Diabetic Retinopathy with fundus images from their patients.

This research work can be further extended and improved. A proper model can be developed to correctly classify all the stages of DR. Improved hardware can provide faster annotation in addition to accuracy.

ACKNOWLEDGMENT

The major work in this paper had been presented in the International Conference on Information Technology and Application (ICITA 2014), 1–4 July, 2014 in Sydney, Australia. In addition, we addressed those issues arose during ICITA 2014 for further improvement in our work.

We would like to think the anonymous volunteers who have agreed to provide the retinal image and other personal data for our research.

REFERENCES

- [1] J. J. Kanski and B. Bowling, Clinical Ophthalmology, 7th ed., Elsevier, 2011, pp. 535-554.
- [2] M. Ashraful Amin and Hong Yan, "High Speed Detection of Blood Vessels in a Retinal Fundus Image using Phase Congruency," *Soft Computing*, 2011, Springer.
- [3] M. Islamuddin Ahmed, M. Ashraful Amin, "High Speed Detection of Optical Disc in Retinal Fundus Image", *Journal of Signal, Image and Video Processing*, 2012, Springer.
- [4] M. Islamuddin Ahmed, M. Ashraful Amin, Bruce Poon, and Hong Yan "Retina Based Biometric Authentication using Phase Congruency", *IJMLC*, 2013, Springer.
- [5] Digital Retinal Image for Vessel Extraction (DRIVE). Available at : <http://www.isi.uu.nl/Research/Databases/DRIVE/>
- [6] VARPA Retina Images Authentication (VARIA) database. Available at : <http://www.varpa.es/varia.html>
- [7] VICAVR Database, <http://www.varpa.es/vicavr.html>
- [8] DIARETDB_01: Standard Diabetic Retinopathy Database. Available at : <http://www2.it.lut.fi/project/imageret/diaretdb1/index.html>
- [9] MESSIDOR: Digital Retinal Images. Available at : <http://messidor.crihan.fr/download.php>
- [10] T. Cover, and P. Hart. "Nearest neighbor pattern classification." *IEEE Transl. Information Theory*, vol. 13, issue. 1, pp. 21-27, 1967.